

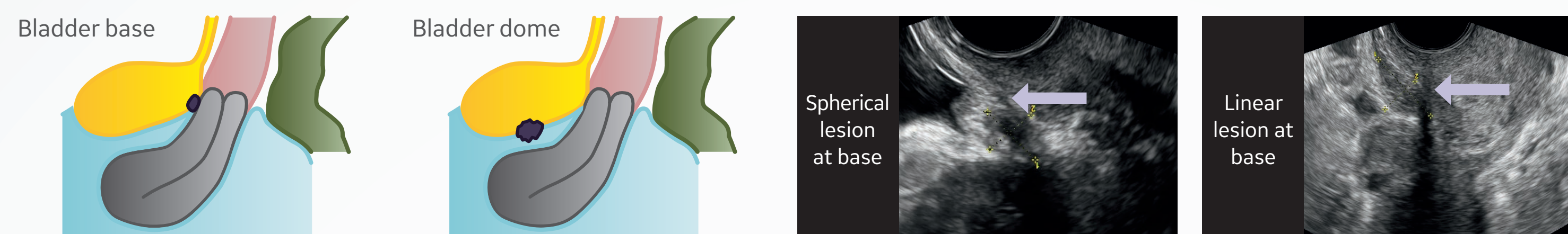
Systematic approach to sonographic evaluation of the pelvis in women with suspected endometriosis, including terms, definitions and measurements



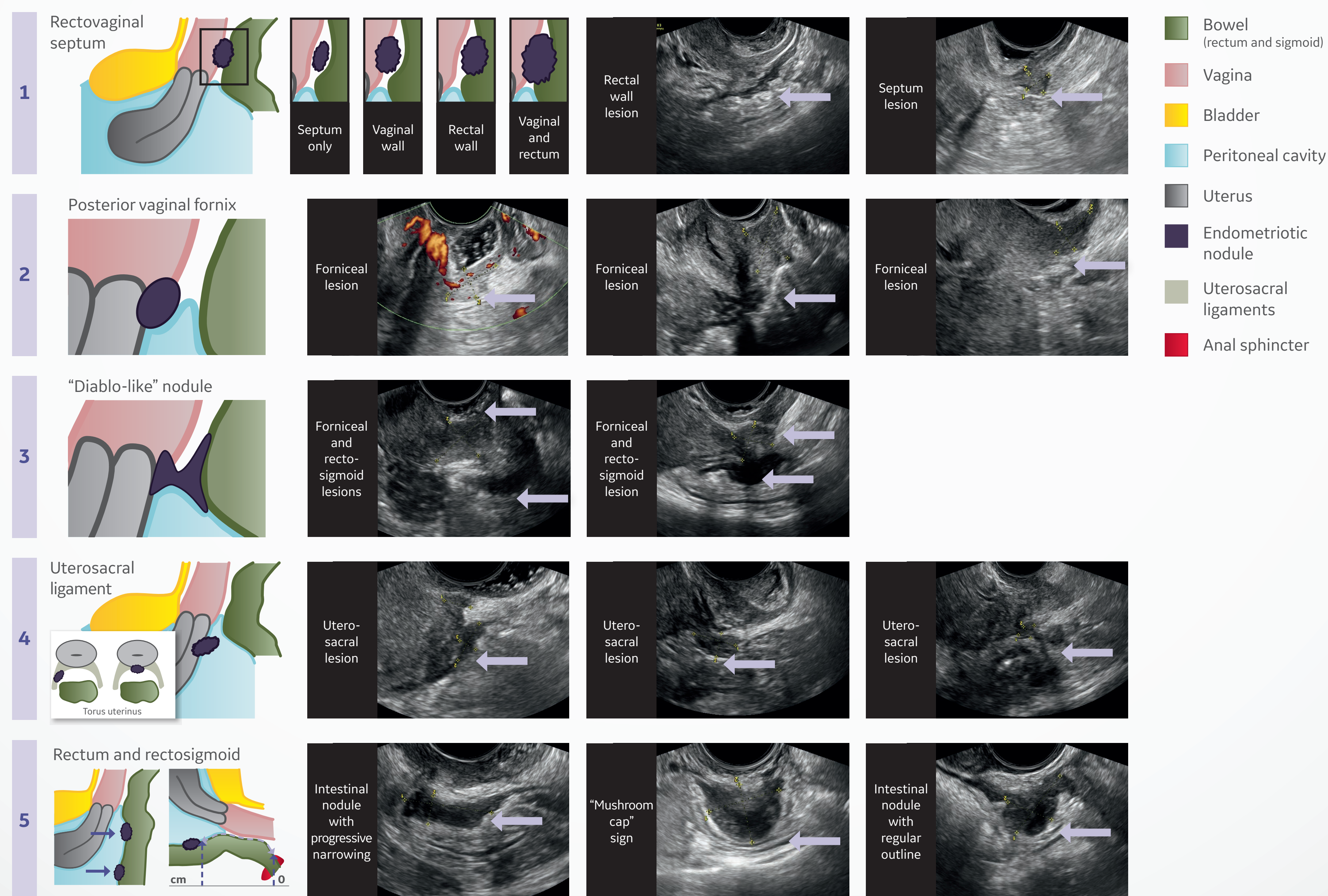
A consensus opinion from the International Deep Endometriosis Analysis (IDEA) group

Ultrasound Obstet Gynecol 2016;48:318-32.

A. ANTERIOR COMPARTMENT



B. POSTERIOR COMPARTMENT



DYNAMIC ULTRASONOGRAPHY

First step: Routine evaluation of uterus and adnexa (+ sonographic signs of adenomyosis/presence or absence of endometrioma)

Second step: Evaluation of transvaginal sonographic "soft markers" (i.e. site-specific tenderness and ovarian mobility)

Third step: Assessment of status of POD using real-time ultrasound-based "sliding sign"

Fourth step: Assessment for DIE nodules in anterior and posterior compartments

© 2018 General Electric Company - All rights reserved.

GE Healthcare reserves the right to make changes in specifications and features shown herein, or discontinue the product described at any time without notice or obligation. Contact your GE Healthcare representative for the most current information. GE and the GE Monogram trademarks of General Electric Company. GE Healthcare, a division of General Electric Company. GE Medical Systems, Inc., doing business as GE Healthcare.

August 2018
JB55334XX